

Left Ventricular Systolic Unloading and Augmentation of Intracoronary Pressure and Doppler Flow During Enhanced External Counterpulsation

Andrew D. Michaels, MD; Michel Accad, MD; Thomas A. Ports, MD; William Grossman, MD

Background—Enhanced external counterpulsation (EECP) is a noninvasive, pneumatic technique that provides beneficial effects for patients with chronic, symptomatic angina pectoris. However, the physiological effects of EECP have not been studied directly. We examined intracoronary and left ventricular hemodynamics in the cardiac catheterization laboratory during EECP.

Methods and Results—Ten patients referred for diagnostic evaluation underwent left heart catheterization and coronary angiography from the radial artery. At baseline and then during EECP, central aortic pressure, intracoronary pressure, and intracoronary Doppler flow velocity were measured using a coronary catheter, a sensor-tipped high-fidelity pressure guidewire, and a Doppler flow guidewire, respectively. Similar to changes in aortic pressure, EECP resulted in a dramatic increase in diastolic (71 ± 10 mm Hg at baseline to 137 ± 21 mm Hg during EECP; +93%; $P < 0.0001$) and mean intracoronary pressures (88 ± 9 to 102 ± 16 mm Hg; +16%; $P = 0.006$) with a decrease in systolic pressure (116 ± 20 to 99 ± 26 mm Hg; -15%; $P = 0.002$). The intracoronary Doppler measure of average peak velocity increased from 11 ± 5 cm/s at baseline to 23 ± 5 cm/s during EECP (+109%; $P = 0.001$). The TIMI frame count, a quantitative angiographic measure of coronary flow, showed a 28% increase in coronary flow during EECP compared with baseline ($P = 0.001$).

Conclusions—EECP unequivocally and significantly increases diastolic and mean pressures and reduces systolic pressure in the central aorta and the coronary artery. Coronary artery flow, determined by both Doppler and angiographic techniques, is increased during EECP. The combined effects of systolic unloading and increased coronary perfusion pressure provide evidence that EECP may serve as a potential mechanical assist device. (*Circulation*. 2002;106:1237-1242.)

Key Words: hemodynamics ■ cardiovascular diseases ■ catheterization ■ blood flow ■ blood pressure

Enhanced external counterpulsation (EECP) is a noninvasive technique that reduces angina and extends time to exercise-induced myocardial ischemia in patients with symptomatic coronary disease.^{1,2} EECP uses the sequential inflation of 3 sets of pneumatic cuffs wrapped around the lower extremities. The cuffs are inflated sequentially (from calf to thigh to buttock) at the onset of diastole, producing aortic counterpulsation, diastolic augmentation, and increased venous return. At the onset of systole, the external pressure in the cuffs is released rapidly, producing a decrease in systolic pressure.

It has been hypothesized that the sustained benefits of EECP result from effective diastolic augmentation that may promote collateral development^{3,4} or improve endothelial function.⁵ Most studies have shown that patients with higher levels of diastolic augmentation measured by finger plethysmography have improved early and late clinical outcomes.⁶⁻⁸

In present practice, EECP is limited to treating outpatients with chronic stable angina pectoris. Early external counterpulsation models involving a lower-extremity hydraulic water-compression system were shown to provide clinical benefit in a small sample of patients with either acute myocardial infarction⁹ or cardiogenic shock.¹⁰⁻¹² Whether the acute hemodynamic effects of the sequential, pneumatic EECP device could benefit inpatients with these acute cardiac disorders is not known.

Measurements of the acute hemodynamic effects during EECP have been limited to noninvasive finger plethysmography,⁶⁻⁸ thoracic electrical bioimpedance methodology,¹³ echocardiography,^{14,15} right heart catheterization,¹⁶ and radial artery catheterization.¹⁶ Because the EECP cuffs cover the femoral site, invasive left heart catheterization or intracoronary hemodynamic studies during EECP have not been performed previously. The purpose of this study was to assess

Received April 9, 2002; revision received June 14, 2002; accepted June 17, 2002.

From the Division of Cardiology, Department of Medicine, University of California at San Francisco Medical Center, San Francisco, Calif.

Dr Michaels is a consultant for Vasomedical, Inc, where he also serves on the Speaker's Bureau.

Correspondence to Andrew D. Michaels, MD, Division of Cardiology, University of California at San Francisco Medical Center, 505 Parnassus Ave, Box 0124, San Francisco, CA 94143-0124. E-mail andrewm@itsa.ucsf.edu

© 2002 American Heart Association, Inc.

Circulation is available at <http://www.circulationaha.org>

DOI: 10.1161/01.CIR.0000028336.95629.B0

intracoronary, central aortic, and cardiac hemodynamics during EECP and to determine whether these acute hemodynamic effects of EECP will have a favorable profile for patients with disorders such as acute coronary syndrome or cardiogenic shock. For this study, left heart catheterization and measurements of intracoronary pressure and Doppler flow velocity were performed from the right radial arterial site at baseline and during EECP.

Methods

Patient Population

Outpatients referred for diagnostic cardiac catheterization and coronary angiography at the University of California-San Francisco (UCSF) Adult Cardiac Catheterization Laboratory were enrolled in this study. Patients were not asked to participate if any of the following were present: severe aortic insufficiency, decompensated congestive heart failure, significant arrhythmia, systolic blood pressure >180 mm Hg, symptomatic peripheral vascular disease, an abnormal Doppler Allen's test of the right upper extremity, or unsuitable (ie, amputation or congenital deformity) lower extremity anatomy. Those with coronary anatomy unsuitable for intracoronary pressure or Doppler velocity guidewire placement (ie, thrombus, excessive tortuosity) were also excluded. All patients gave written informed consent before the procedure, and the protocol was approved by the UCSF Committee on Human Research.

Study Procedures

A 6F sheath was inserted in the right radial artery. After diagnostic cardiac catheterization, coronary angiography, and full heparinization, a 0.014-inch sensor-tipped high-fidelity pressure guidewire (PressureWire 3 sensor, Radi Medical Systems) and a 0.014-inch Doppler velocity guidewire (FloWire, Jomed) were positioned in the mid-to-distal portion of an unobstructed coronary artery under fluoroscopic guidance.

EECP (model TS3, Vasomedical) was performed while simultaneously measuring central aortic pressure using the coronary catheter, intracoronary pressure using the PressureWire, and intracoronary Doppler flow velocities using the FloWire. Peak and area under curve (by planimetry) pressures were recorded for central aortic and intracoronary pressures. For planimetry, the timing of the onset of diastole was at the dicrotic notch, and the onset of systole was at the systolic upstroke. At baseline, diastolic pressure was measured at end-diastole. Measurements of hemodynamic variables and coronary blood flow were reported for the maximal augmented diastolic pressure and flow attained during counterpulsation. Coronary angiography (General Electric Advantx with Camtronics Medical Systems digital processing) was performed at baseline and during EECP. The corrected TIMI frame count (CTFC) was measured as described previously.¹⁷ After removal of the guidewires, left ventricular and radial artery pressures were recorded at baseline and during EECP. To assess systolic unloading, hemodynamics were recorded during EECP at both 1:1 (every QRS complex) and 1:2 (every other QRS complex) counterpulsations.

EECP Therapy

The EECP device (model TS3, Vasomedical) is composed of an air compressor, a computer module, a set of cuffs, and a treatment table. Before cardiac catheterization, the cuffs were wrapped around both calves and the lower and upper thighs (including the buttocks) of the patient. During the cardiac catheterization procedure, patients remained on the catheterization table and the cuffs were connected by air hoses to the air compressor unit. The EECP device inflates the cuffs with air and then deflates them in a sequence that is synchronized with the patient's cardiac cycle. Pressure is applied sequentially from the calves to the buttocks, starting in early diastole. At the end of diastole, the compressed air is released rapidly from the cuffs to remove the externally applied pressure. EECP was performed at external cuff pressures ranging from 100 to 300 mm Hg.

Intracoronary Doppler Velocity Protocol

The Doppler guidewire FloWire system has a miniature Doppler ultrasound crystal that transmits signals at a carrier frequency of 15 MHz and received pulsed-wave ultrasound signals, sampled at a distance of 5 mm from the guidewire tip. The Doppler signals are analyzed by a FloMap instrument (Jomed), in which dedicated digital signal-processing chips perform the fast Fourier transformation required for the spectral display. The spectrum and the ECG are simultaneously displayed on the monitor. Also displayed were quantitative measurements of average peak velocity (APV) and diastolic to systolic velocity ratio (DSVR). The monitor display was continuously recorded on a high-quality super-VHS (S-VHS, Fuji) videotape for subsequent offline analysis.

Statistical Analysis

Data are presented as mean values and SDs for continuous variables. Comparisons between the baseline hemodynamic values and those during EECP were assessed using a paired two-tailed Student's *t* test for paired observations. Associations between the measures of coronary flow were calculated via Pearson's correlation coefficients. $P < 0.05$ was considered significant.

Results

Patient Population

Ten outpatients were enrolled. Seven patients were men, and the mean age was 55.7 ± 10.7 years (range, 36 to 69 years). The indications for cardiac catheterization were the following: suspected coronary artery disease ($n=5$), severe mitral regurgitation before mitral valve repair ($n=3$), and prior orthotopic heart transplantation for annual surveillance cardiac catheterization ($n=2$). Five patients had a history of hypertension, 5 had hyperlipidemia, and 2 had diabetes mellitus. Three patients had significant coronary artery disease with at least one $\geq 75\%$ diameter stenosis, whereas one patient had marked slow coronary flow attributable to severe coronary artery ectasia. All patients had normal left ventricular systolic function. Renal function was normal in all patients except one non-dialysis-dependent diabetic woman with a serum creatinine of 4.6 mg/dL. None were active smokers, and none had clinically significant peripheral vascular disease.

Left Heart and Systemic Hemodynamics

Simultaneous central aortic and intracoronary pressure were recorded at the start of EECP (Figure 1). Peak aortic systolic pressure decreased 11% from 114 ± 19 mm Hg at baseline to 101 ± 28 mm Hg during EECP ($P=0.02$). Aortic diastolic pressure increased 92% from 71 ± 10 mm Hg to 136 ± 22 mm Hg during EECP ($P < 0.0001$). Mean aortic pressure increased 16% from 88 ± 10 mm Hg at baseline to 102 ± 14 mm Hg during EECP ($P=0.0007$). The effects of systolic unloading are demonstrated during EECP at 1:2 counterpulsation (Figure 2). Left ventricular end-diastolic pressure had a non-statistically significant trend toward decreasing during EECP (15 ± 7 mm Hg at baseline, 13 ± 6 mm Hg during EECP; $P=0.17$).

Intracoronary Hemodynamics

We studied the dominant right coronary artery in 6 patients, the dominant left circumflex artery in 2 patients, the left anterior descending coronary artery in 1 patient, and the ramus intermedius in 1 patient.

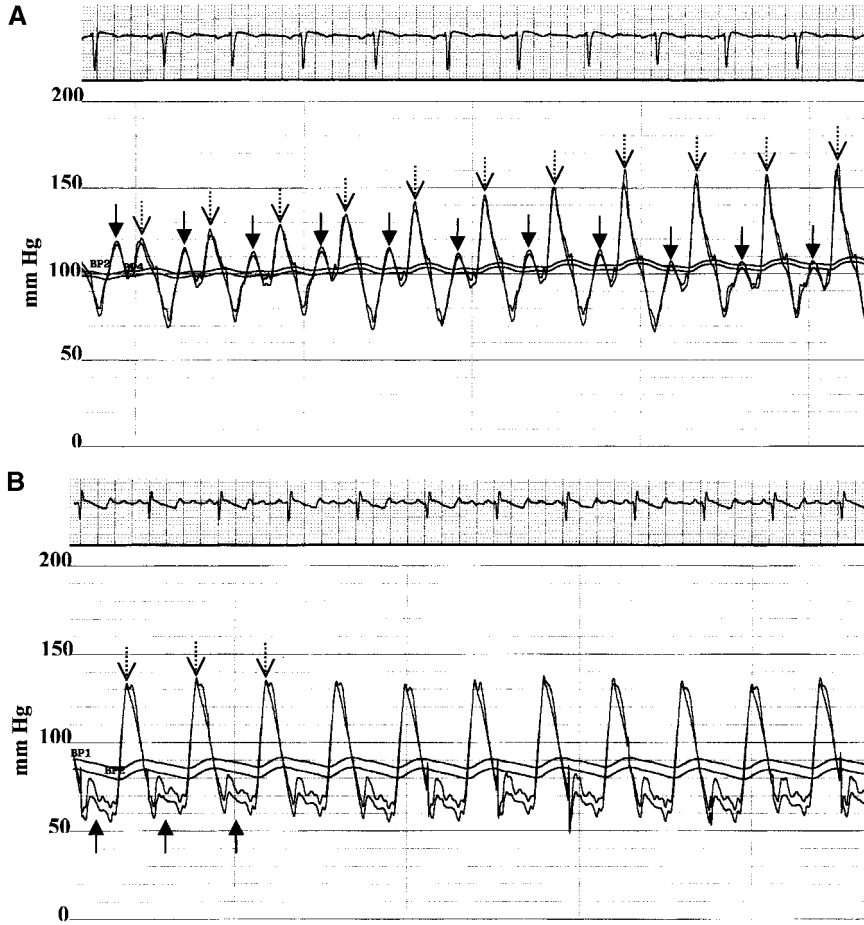


Figure 1. Representative simultaneous hemodynamic tracings of central aortic pressure from the coronary catheter and intracoronary pressure from the PressureWire. In tracings of both phasic and mean pressure (bottom) obtained at the beginning of EECP (A), there is a gradual increase in peak diastolic (dashed arrows) and mean pressure with a decrease in peak systolic pressure (solid arrows) attributable to systolic unloading as the inflation pressure is increased in the EECP device. In another patient, diastolic augmentation is demonstrated during EECP at a cuff pressure of 300 mm Hg (B). The intracoronary coronary pressure was 5 mm Hg lower than central aortic pressure, attributable to diffuse coronary atherosclerosis. The paper speed is 25 mm/sec.

Intracoronary Pressure

The PressureWire was used in an unobstructed coronary artery to measure intracoronary pressure in 9 patients at baseline and during EECP. Similar to central aortic pressure measurements, there was an increase in intracoronary peak diastolic pressure (71 ± 10 mm Hg at baseline; 137 ± 21 mm Hg during EECP; +93%; $P < 0.0001$; Figure 3) and mean pressure (88 ± 9 mm Hg at baseline; 102 ± 16 mm Hg during EECP; +16%; $P = 0.006$), with a decrease in peak systolic pressure (116 ± 20 mm Hg at baseline; 99 ± 26 mm Hg during EECP; -15%; $P = 0.002$).

Planimetry of the intracoronary pressure tracings similarly showed an increase in diastolic pressure (42 ± 9 mm Hg · sec at

baseline; 54 ± 15 mm Hg · sec during EECP; +28%; $P = 0.0003$) and a decrease in systolic pressure (33 ± 6 mm Hg · sec at baseline; 29 ± 7 mm Hg · sec during EECP; -12%; $P = 0.008$). The changes in intracoronary systolic, diastolic, and mean pressure were compared at increasing EECP inflation pressure (Figure 4).

Intracoronary Doppler Flow Velocity

The FloWire was used to measure intracoronary Doppler velocity at baseline and during EECP in 8 patients (Figure 5). The APV increased from 11 ± 5 cm/s at baseline to 23 ± 5 cm/s during EECP (+109%; $P = 0.001$; Table). The peak

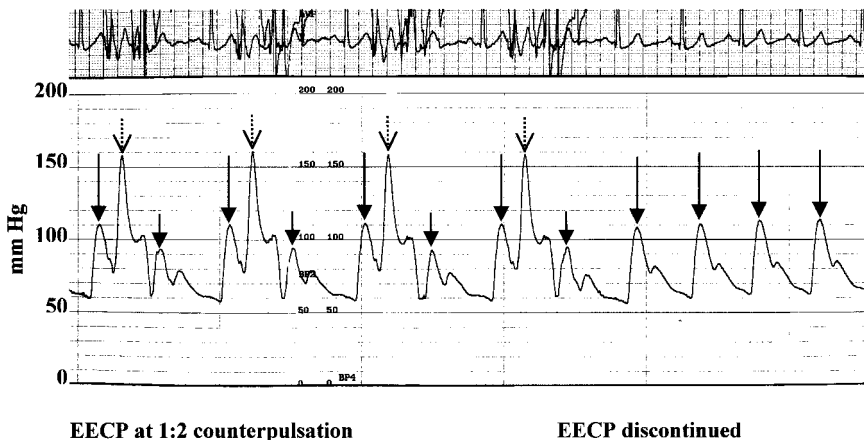


Figure 2. Arterial pressure tracings demonstrating the effects of systolic unloading with EECP. EECP is performed at 1:2 counterpulsation, with cuff inflation with every other diastolic period. The assisted systolic pressure (short solid arrows) after diastolic augmentation (dashed arrows) is lower than the unassisted systole (long solid arrows). When EECP is discontinued, systolic pressure returns to the level equal to the unassisted systolic pressure. Artifact on the ECG (top) is attributable to EECP-related chest wall motion. The paper speed is 25 mm/sec.

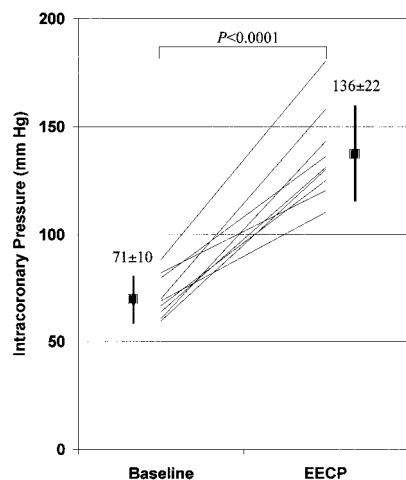


Figure 3. Intracoronary diastolic pressure at baseline and during EECP (n=9). The mean values with SD error bars are shown.

diastolic velocity increased from 18 ± 7 cm/s at baseline to 45 ± 14 cm/s during EECP (+150%; $P=0.0004$; Figure 6). The correlation coefficient was 0.95 comparing percent changes in APV with peak diastolic velocity. The DSVR increased from 1.0 ± 0.3 to 2.0 ± 0.7 during EECP (+100%; $P=0.003$). There was no significant change in peak systolic velocity.

Corrected TIMI Frame Count

All 10 patients had a CTFC calculated at baseline and during EECP. Showing an increase in coronary blood velocity, the CTFC significantly decreased from 37 ± 18 at baseline to 27 ± 13 during EECP, corresponding to a 28% increase in coronary blood velocity ($P=0.001$; Table). The correlation coefficient was 0.55 comparing percent changes in CTFC with peak diastolic velocity and 0.54 for percent changes in CTFC and APV. In the only patient with TIMI flow grade 2 attributable to severe coronary ectasia, the right coronary artery TFC decreased from 81 frames at baseline to 53 frames during EECP (53% faster coronary velocity).

Discussion

This study demonstrates that EECP unequivocally and dramatically increases directly measured coronary flow velocity and pressure. This noninvasive counterpulsation technique generates a significant increase in diastolic pressure measured in the central aorta and the mid to distal coronary artery, representing diastolic augmentation during balloon inflation. Coronary blood flow velocity measured by both angiographic and intracoronary Doppler techniques is significantly increased during EECP, whereas left ventricular afterload is reduced because of systolic unloading, thereby lowering left ventricular work. Results of our study provide new insight into the hemodynamic effectiveness and potential clinical applications of EECP.

The hemodynamic evaluation of external counterpulsation began in the mid 1960s with the application of a water-filled bag wrapped around the legs to treat patients with cardiogenic shock. Soroff and colleagues^{18–20} were the first investigators who applied external counterpulsation in humans. Among 20 patients with cardiogenic shock treated with external counterpulsation, the mortality rate of 65% was reported to be lower than contemporary rates for those treated with intra-aortic balloon pumping (IABP).¹¹ It was felt that this early external counterpulsation device improved hemodynamics and myocardial metabolism in cardiogenic shock but was not powerful enough to fully reverse shock.²¹

Early external counterpulsation devices were evaluated in patients with acute myocardial infarction. External counterpulsation seemed to prevent the hypotension caused by nitroprusside vasodilator therapy, providing left ventricular systolic unloading pharmacologically while maintaining coronary perfusion by external counterpulsation.²² In a large multicenter study of 258 patients with acute myocardial infarction, patients were randomized to external counterpulsation within 24 hours of presentation or usual care.²³ Patients assigned to the external counterpulsation group had a trend toward lower hospital mortality rate (8.4%) compared with controls (14.7%; $P=NS$). Patients in the external counterpulsation group had lower rates of recurrent chest pain, progres-

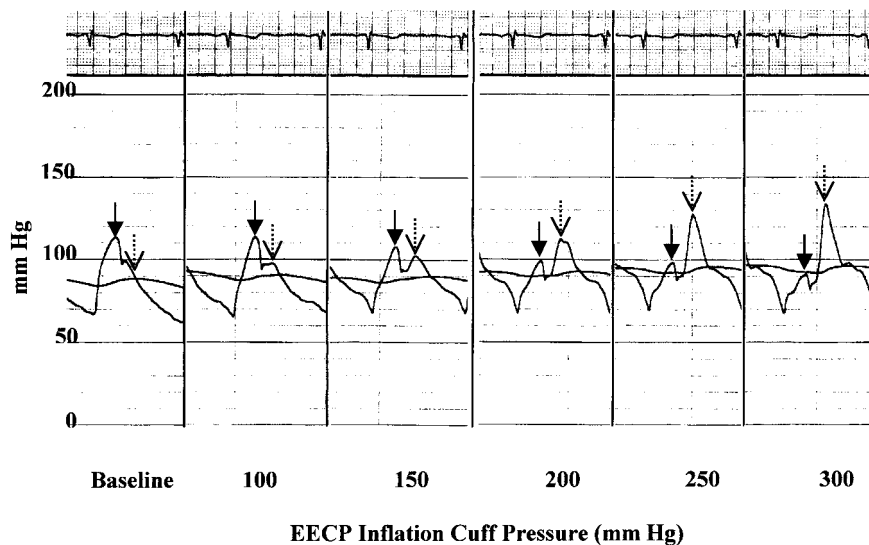


Figure 4. Intracoronary phasic and mean pressure tracings at baseline and at increasing cuff inflation pressure in the EECP device. With increasing inflation pressure, the diastolic (dashed arrows) and mean pressures increase, whereas the systolic pressure (solid arrows) decreases. The paper speed is 25 mm/sec.

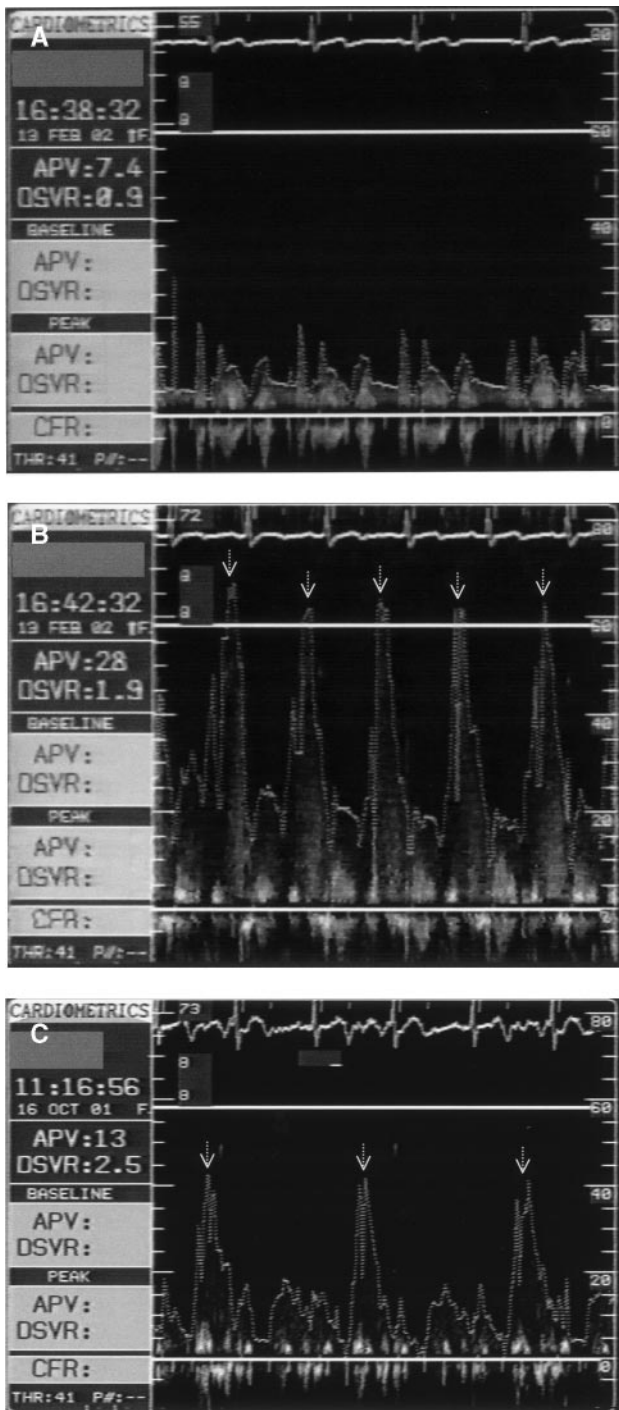


Figure 5. Representative Doppler flow velocities obtained with the FloWire in the right coronary artery at baseline (A), during EECF with 1:1 counterpulsation (B), and from another patient during EECF with 1:2 counterpulsation (C). The APV and DSVR are calculated by the FloMap for each tracing. Diastolic augmentation is identified by the dashed arrows.

sion of heart failure, ventricular fibrillation, and improved cardiac functional status at discharge.

However, there were significant limitations of these early external counterpulsation devices. First, the water-driven leg compression bags were not powerful enough to result in effective systolic unloading; in direct comparisons between IABP and external counterpulsation; the latter did not lower

Intracoronary Velocities at Baseline and During EECF

	Baseline	EECF	P
Angiographic assessment (n=10)			
Corrected TIMI frame count	37±18	27±13	0.001
Doppler FloWire assessment (n=8)			
Average peak velocity, cm/s	11±5	23±5	0.001
Peak systolic velocity, cm/s	17±8	16±7	0.59
Peak diastolic velocity, cm/s	18±7	45±14	0.0004
Diastolic-to-systolic velocity ratio	1.0±0.3	2.0±0.7	0.003

systolic pressure.²¹ Studies of cardiac metabolism showed that IABP decreased myocardial oxygen consumption, resulting in improved myocardial metabolism, whereas external counterpulsation increased oxygen consumption.²¹ In studies measuring coronary sinus blood flow^{24,25} and changes during atrial pacing stress testing,²⁴ external counterpulsation had no acute beneficial metabolic or hemodynamic effects.

Unlike the limitations of earlier external counterpulsation devices, our study shows that EECF seems to have similar effects on the central and systemic arterial system compared with those of IABP. The hemodynamic effects achieved with EECF in this study are roughly comparable to data reported in a study of IABP²⁶: (1) diastolic pressure increased from baseline 92% with EECF and 80% with IABP; (2) mean pressure increased 16% with EECF and 42% with IABP; (3) systolic pressure decreased 11% with EECF and 6% with IABP; (4) mean coronary flow velocity increased 109% with EECF and 67% with IABP; and (5) diastolic flow velocity increased 150% with EECF and 103% with IABP. An important difference in comparing these two studies is that this study using EECF enrolled stable outpatients, whereas the IABP study examined critically ill patients in cardiogenic shock. By displacing the volume of arterial blood from the ankles to the buttocks, EECF potentially may displace a greater blood volume during aortic counterpulsation compared with the 30 to 40 mL displaced by IABP.

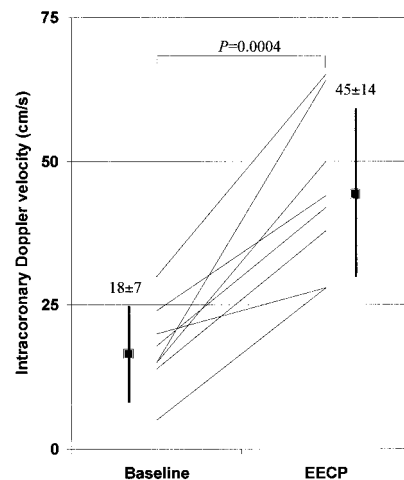


Figure 6. Intracoronary peak diastolic Doppler flow velocity at baseline and during EECF (n=8). The mean values with SD error bars are shown.

In addition to diastolic augmentation, there is clear left ventricular systolic unloading and an overall increase in central mean arterial pressure with EECP. The EECP cuffs provide a noninvasive, pressure-dependent, titratable level of diastolic augmentation, mean pressure augmentation, and systolic unloading. It is recognized that unlike IABP, EECP also increases venous return and preload by compressing the venous system in the lower extremities.¹⁶ The safety of also increasing preload is one of the focuses of studies of EECP in patients with left ventricular systolic dysfunction.²⁷

Study Limitations

A limitation of this study is that the study subjects were hemodynamically stable. We excluded those with pulmonary congestion or systemic hypotension. We assessed intracoronary hemodynamics in unobstructed coronary arteries. It would be expected that changes in coronary pressure and flow velocity during EECP would be diminished with severe epicardial coronary artery stenoses. We also determined intracoronary pressure and Doppler flow velocity changes immediately after initiating EECP, before the attenuation of flow changes attributable to coronary autoregulation. It is possible that coronary flow changes attributable to EECP may have been reduced over time because of autoregulation. The validation and limitations of the CTFC,¹⁷ intracoronary PressureWire,²⁸ and intracoronary Doppler FloWire²⁹ techniques are well described.

Conclusions

Treatment with EECP unequivocally and significantly increases central aortic and intracoronary diastolic pressure and intracoronary blood flow velocity. Mean aortic and intracoronary pressure is increased, and left ventricular systolic unloading occurs during EECP. These central aortic, intracoronary, and left ventricular hemodynamic benefits provide hemodynamic evidence that EECP may serve as a noninvasive hemodynamic support device. The present study should encourage clinical trials evaluating EECP to support patients with cardiogenic shock or impaired coronary blood flow.

Acknowledgments

This study was supported by grants from the American Heart Association Beginning Grant-in-Aid and the UCSF School of Medicine Research Evaluation & Allocation Committee. Dr Michaels is supported by the GlaxoSmithKline Development Partners' Junior Faculty Award. We wish to acknowledge the following contributions: the patients who participated in this study, James Madden, RN, the staff in the UCSF Cardiac Catheterization Laboratory for their superb technical assistance, and Vasomedical, Inc. for technical support.

References

- Arora RR, Chou TM, Jain D, et al. The multicenter study of enhanced external counterpulsation (MUST-EECP): effect of EECP on exercise-induced myocardial ischemia and anginal episodes. *J Am Coll Cardiol*. 1999;33:1833-1840.
- Lawson WE, Hui JC, Cohn PF. Long-term prognosis of patients with angina treated with enhanced external counterpulsation: five-year follow-up study. *Clin Cardiol*. 2000;23:254-258.
- Reidy MA. Factors controlling smooth muscle proliferation. *Arch Pathol Lab Med*. 1992;116:1276-1280.
- Urano H, Ikeda H, Ueno T, et al. Enhanced external counterpulsation improves exercise tolerance, reduces exercise-induced myocardial ischemia and improves left ventricular diastolic filling in patients with coronary artery disease. *J Am Coll Cardiol*. 2001;37:93-99.
- Masuda D, Nohara R, Hirai T, et al. Enhanced external counterpulsation improved myocardial perfusion and coronary flow reserve in patients with chronic stable angina: evaluation by ¹³N-ammonia positron emission tomography. *Eur Heart J*. 2001;22:1451-1458.
- Michaels AD, Kennard ED, Kelsey SF, et al. Does higher diastolic augmentation predict clinical benefit from enhanced external counterpulsation? Data from the international EECP patient registry (IEPR). *Clin Cardiol*. 2001;24:453-458.
- Lakshmi MV, Kennard ED, Kelsey SF, et al. Relation of the pattern of diastolic augmentation during a course of enhanced external counterpulsation (EECP) to clinical benefit [from the International EECP Patient Registry (IEPR)]. *Am J Cardiol*. 2002;89:1303-1305.
- Stys T, Lawson WE, Hui JC, et al. Acute hemodynamic effects and angina improvement with enhanced external counterpulsation. *Angiology*. 2001;10:653-658.
- Amsterdam EA, DeMaria AN, Lee G, et al. Mechanical circulatory assist in acute ischemic heart disease. *Adv Cardiol*. 1978;23:142-162.
- Soroff HS, Birtwell WC. Clinical evaluation in synchronous external counterpulsation in cardiogenic shock. *J Cardiovasc Surg*. 1973;14:752-756.
- Soroff HS, Cloutier CT, Birtwell WC, et al. External counterpulsation: management of cardiogenic shock after myocardial infarction. *JAMA*. 1974;229:1441-1450.
- Cohen LS, Mullins CB, Mitchell JH. Sequenced external counterpulsation and intraaortic balloon pumping in cardiogenic shock. *Am J Cardiol*. 1973;32:656-661.
- Arora RR, Carlucci ML, Malone AM, et al. Acute and chronic hemodynamic effects of enhanced external counterpulsation in patients with angina pectoris. *J Invest Med*. 2001;49:500-504.
- Werner D, Schneider M, Weise M, et al. Pneumatic external counterpulsation: a new noninvasive method to improve organ perfusion. *Am J Cardiol*. 1999;84:950-952.
- Suresh K, Simandl S, Lawson WE, et al. Maximizing the hemodynamic benefit of enhanced external counterpulsation. *Clin Cardiol*. 1998;21:649-653.
- Taguchi I, Ogawa K, Oida A, et al. Comparison of hemodynamic effects of enhanced external counterpulsation and intra-aortic balloon pumping in patients with acute myocardial infarction. *Am J Cardiol*. 2000;86:1139-1141.
- Gibson CM, Cannon CP, Daley WL, et al. The TIMI frame count: a quantitative method of assessing coronary artery flow. *Circulation*. 1996;93:879-888.
- Soroff HS, Birtwell WC, Giron F, et al. Support of systemic circulation and left ventricular assist by synchronous pulsation of extramural pressure. *Surg Forum*. 1965;16:148-150.
- Giron F, Birtwell WC, Soroff HS, et al. Assisted circulation by synchronous pulsation of extramural pressure. *Surgery*. 1966;60:894-901.
- Ruiz U, Soroff HS, Birtwell WC, et al. External synchronous assisted circulation: experimental and clinical evaluation. *Surg Forum*. 1968;19:127-128.
- Mueller H. Are intra-aortic balloon pumping and external counterpulsation effective in the treatment of cardiogenic shock? *Cardiovasc Clin*. 1977;8:87-102.
- Parmley WW, Chatterjee K, Charuzi Y, et al. Hemodynamic effects of noninvasive systolic unloading (nitroprusside) and diastolic augmentation (external counterpulsation) in patients with acute myocardial infarction. *Am J Cardiol*. 1974;33:819-825.
- Amsterdam EA, Banas J, Criley JM, et al. Clinical assessment of external pressure circulatory assistance in acute myocardial infarction: report of a cooperative clinical trial. *Am J Cardiol*. 1980;45:349-356.
- Solignac A, Ferguson RJ, Bourassa MG. External counterpulsation: coronary hemodynamics and use in treatment of patients with stable angina pectoris. *Cathet Cardiovasc Diagn*. 1977;3:37-45.
- Kern MJ, Henry RH, Lembo N, et al. Effects of pulsed external augmentation of diastolic pressure on coronary and systemic hemodynamics in patients with coronary artery disease. *Am Heart J*. 1985;110:727-735.
- Kern MJ, Aguirre FV, Tatineni S, et al. Enhanced coronary blood flow velocity during intraaortic balloon counterpulsation in critically ill patients. *J Am Coll Cardiol*. 1993;21:359-368.
- Soran O, Fleishman B, Demarco T, et al. Enhanced external counterpulsation in patients with heart failure: a multicenter feasibility study. *Congest Heart Fail*. 2002;8:204-208.
- Pijls NH, De Bruyne B, Bech GJ, et al. Coronary pressure measurement to assess the hemodynamic significance of serial stenoses within one coronary artery: validation in humans. *Circulation*. 2000;102:2371-2377.
- Dib N, Bajwa T, Shalev T, et al. Validation of Doppler FloWire for measurement of coronary flow reserve in humans. *Cathet Cardiovasc Diagn*. 1998;45:382-385.